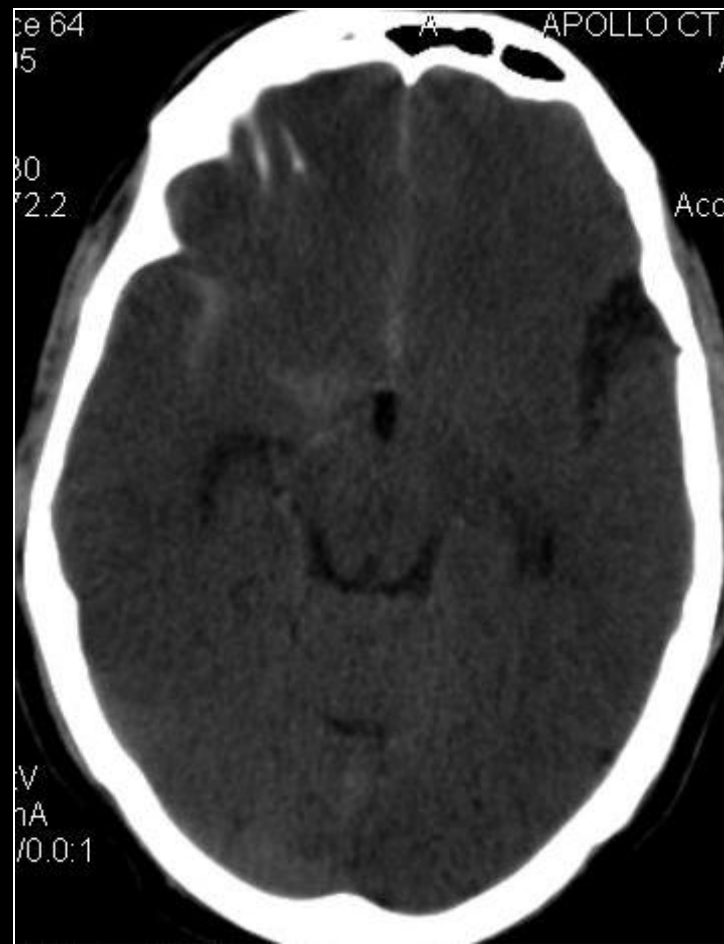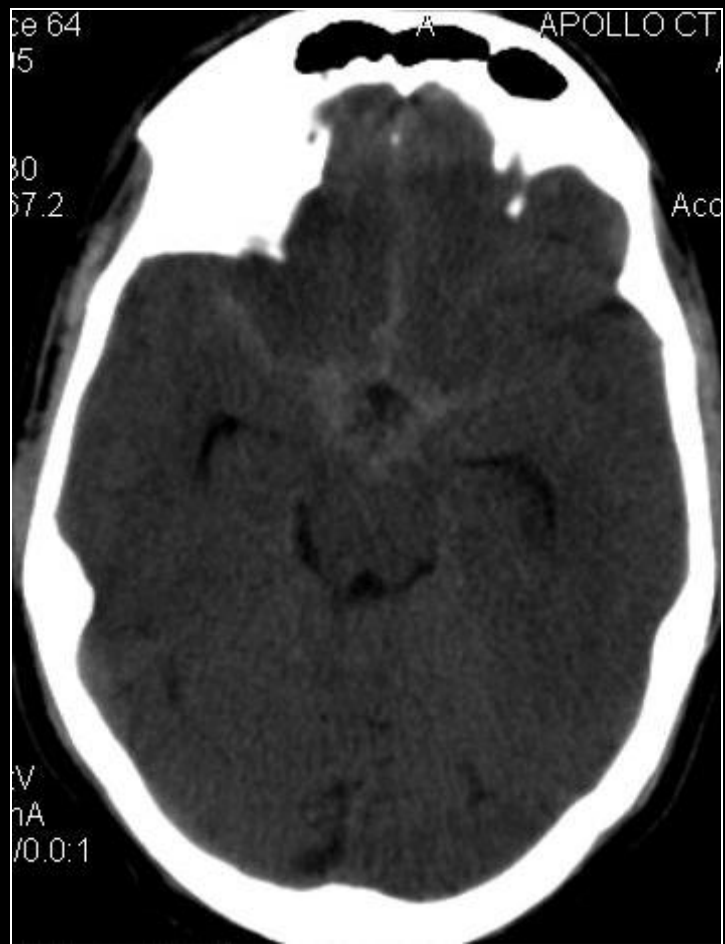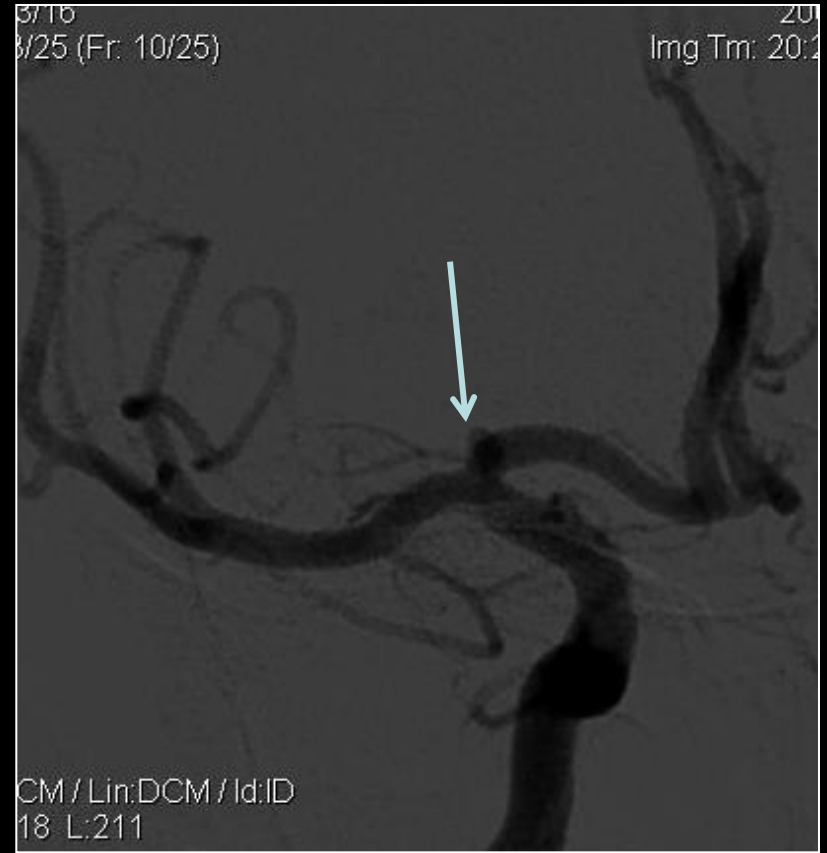


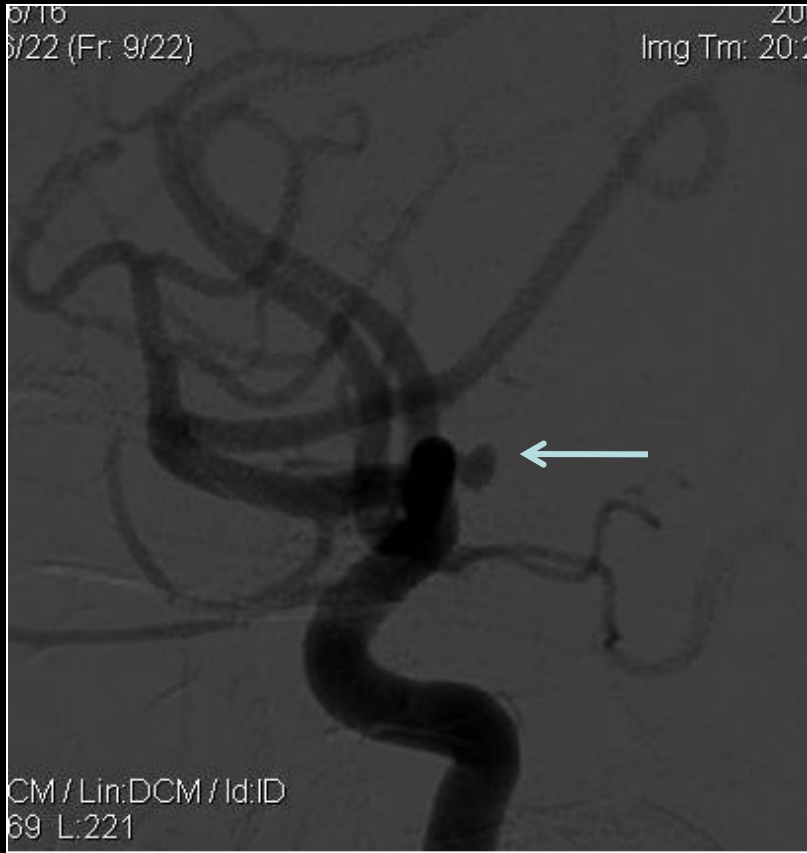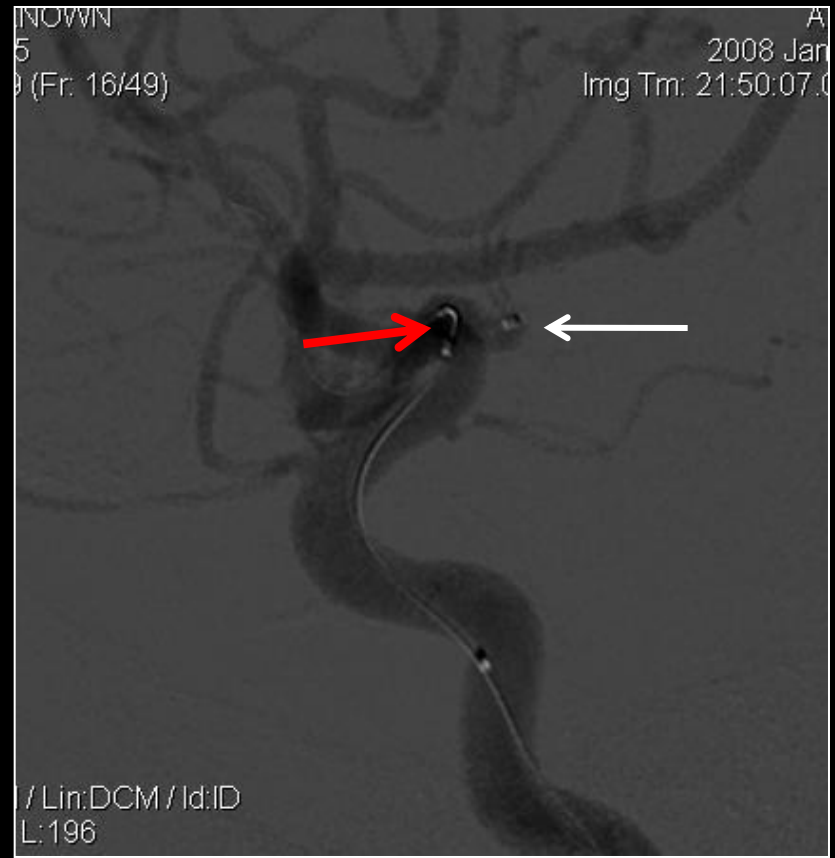- Typical presentation of SAH.
  - Severe headache early morning.
  - Vomiting,
  - Drowsy.
- 
- CT study showed diffuse SAH.

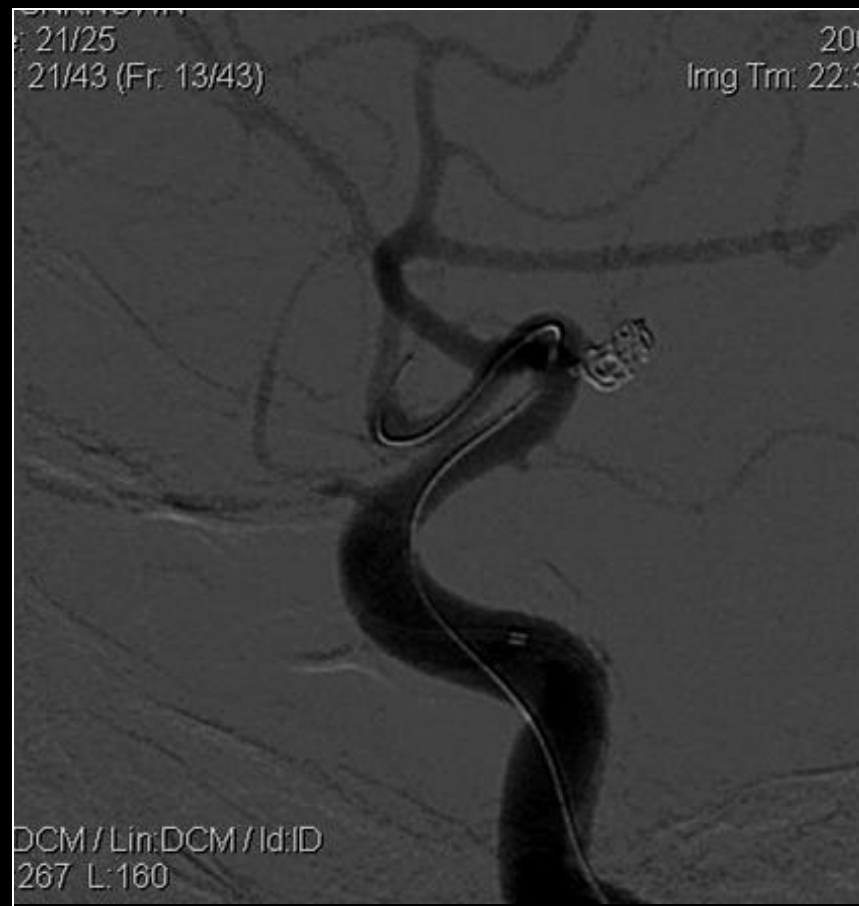
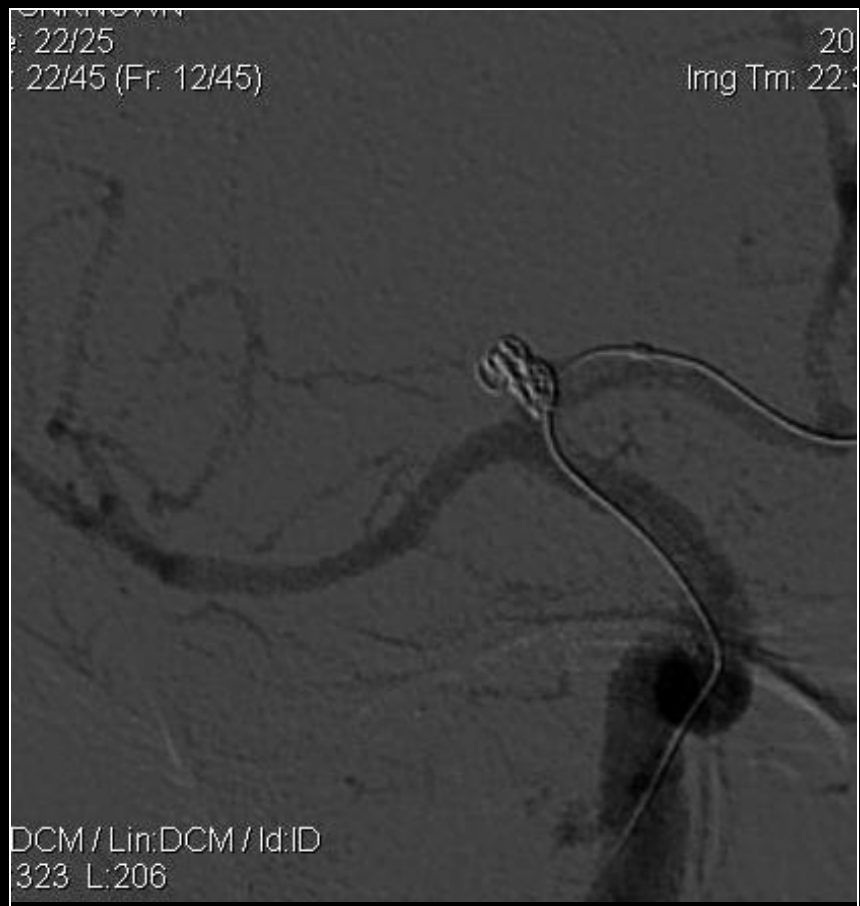


Cerebral DSA reveals wide neck ICA top / proximal A1 segment Aneurysm



Hyperform: 4mm X 7mm. placed across neck of aneurysm (Red Arrows)  
Echelon 14 X Xpedion 14 micro-catheter (white arrow) was placed in the sac and subsequently coiled



- Procedure time was approximately 2 hrs.
- No intra-procedural complication noted.
- Patient was observed in Neuro-ICU for 2 days.
- Was discharged after 4-5 days.
- No fresh complaints, on clinical follow up.